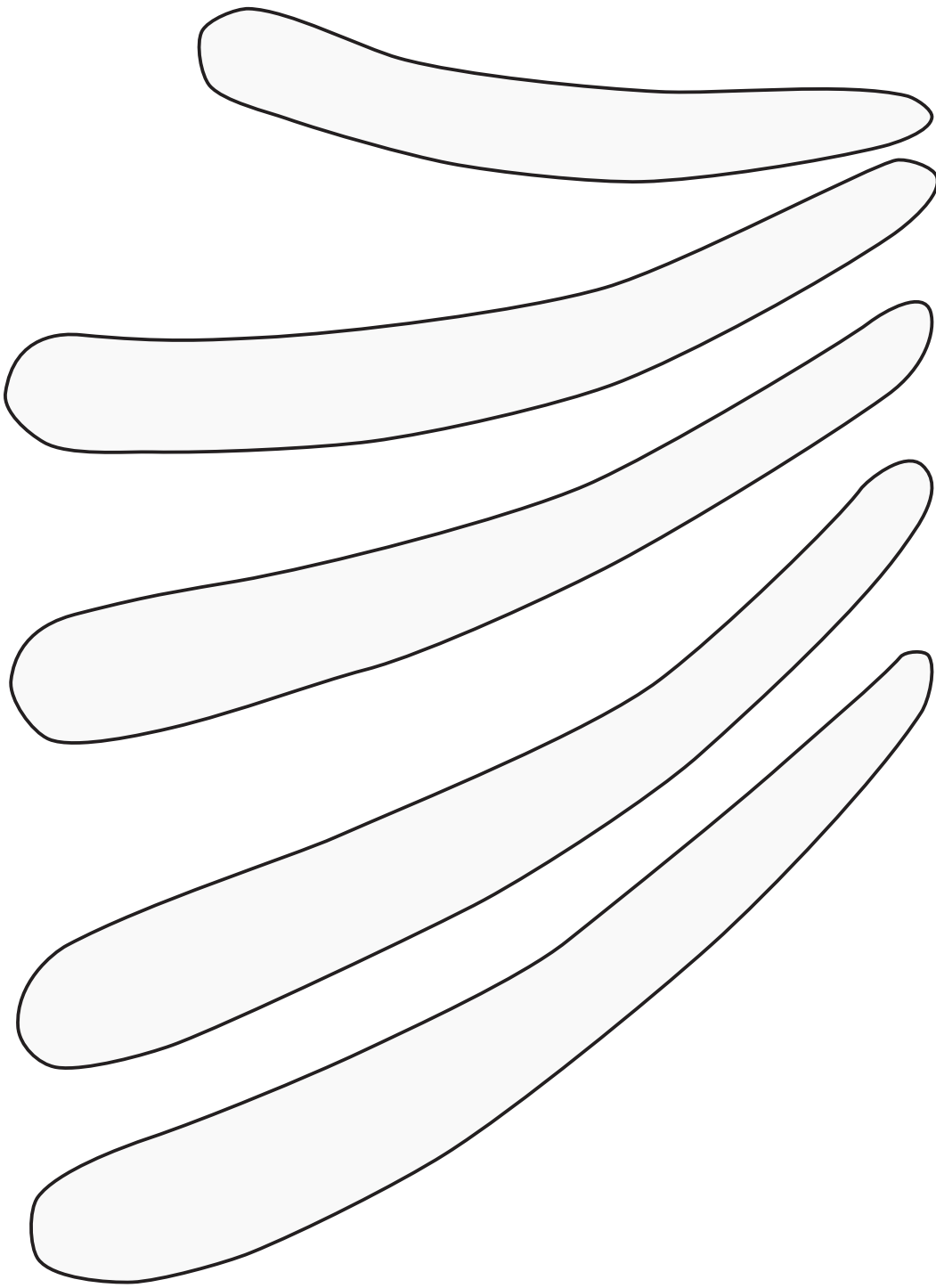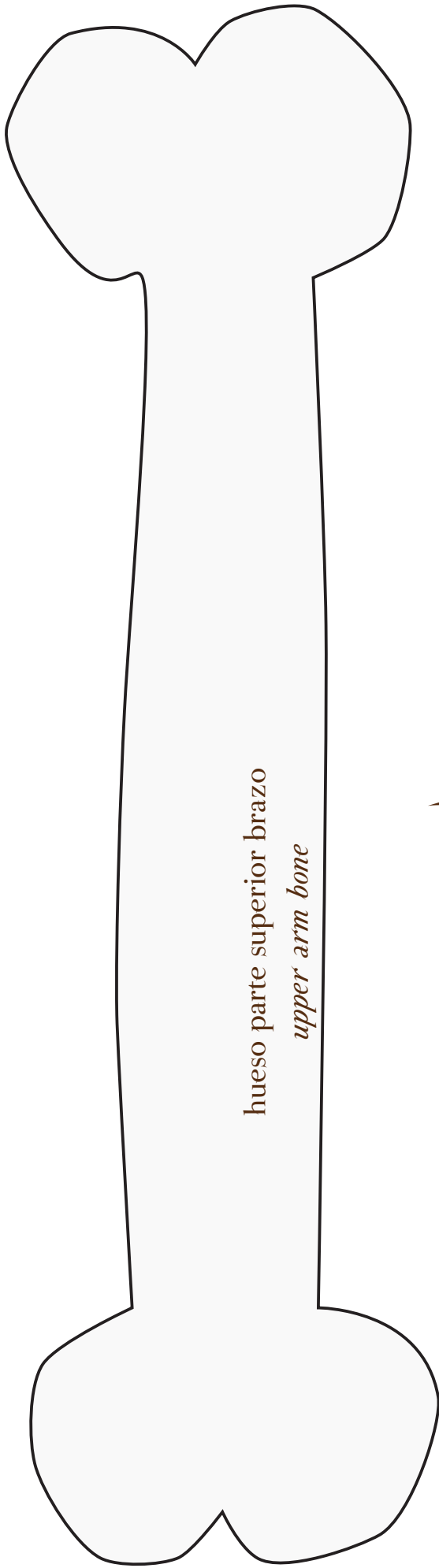


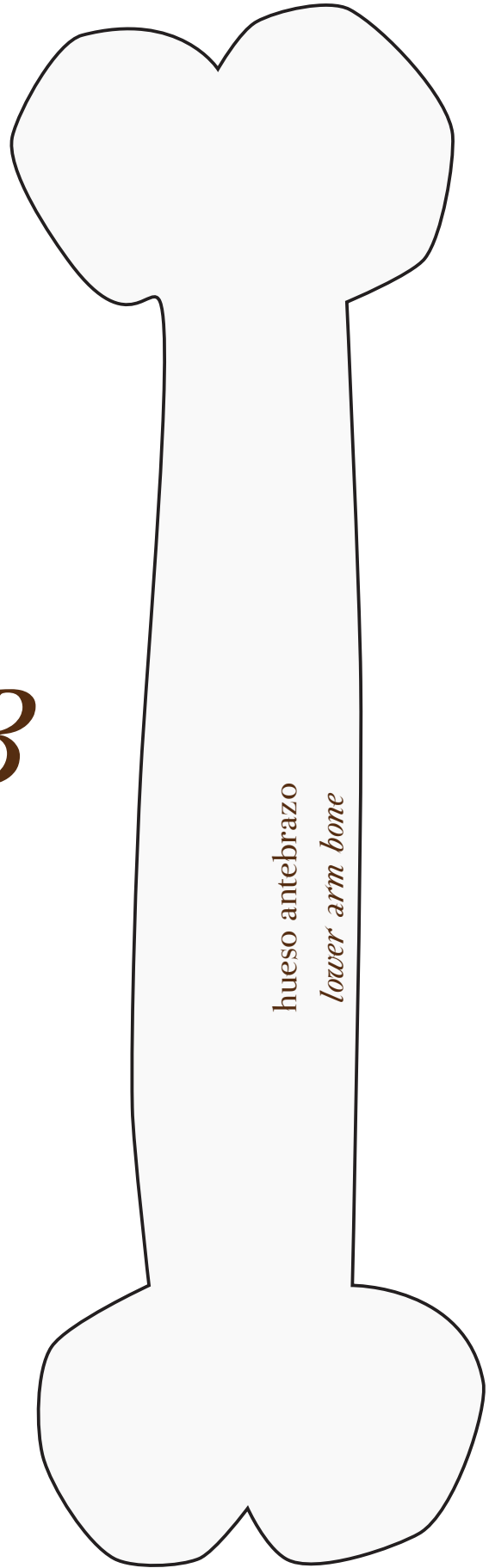
A





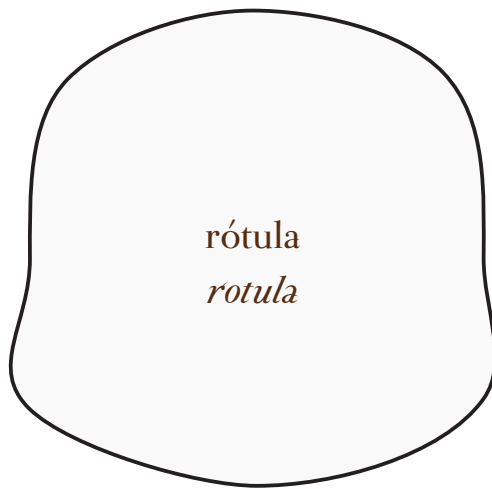
hueso parte superior brazo
upper arm bone

B

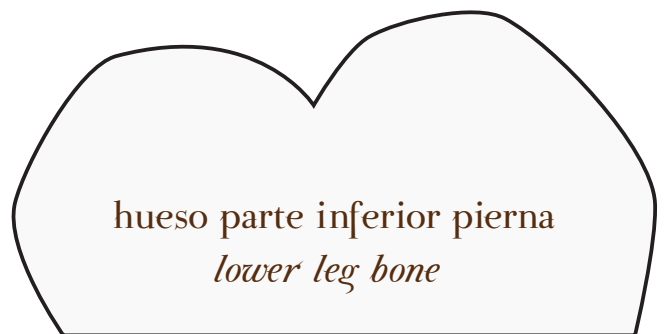


hueso antebrazo
lower arm bone



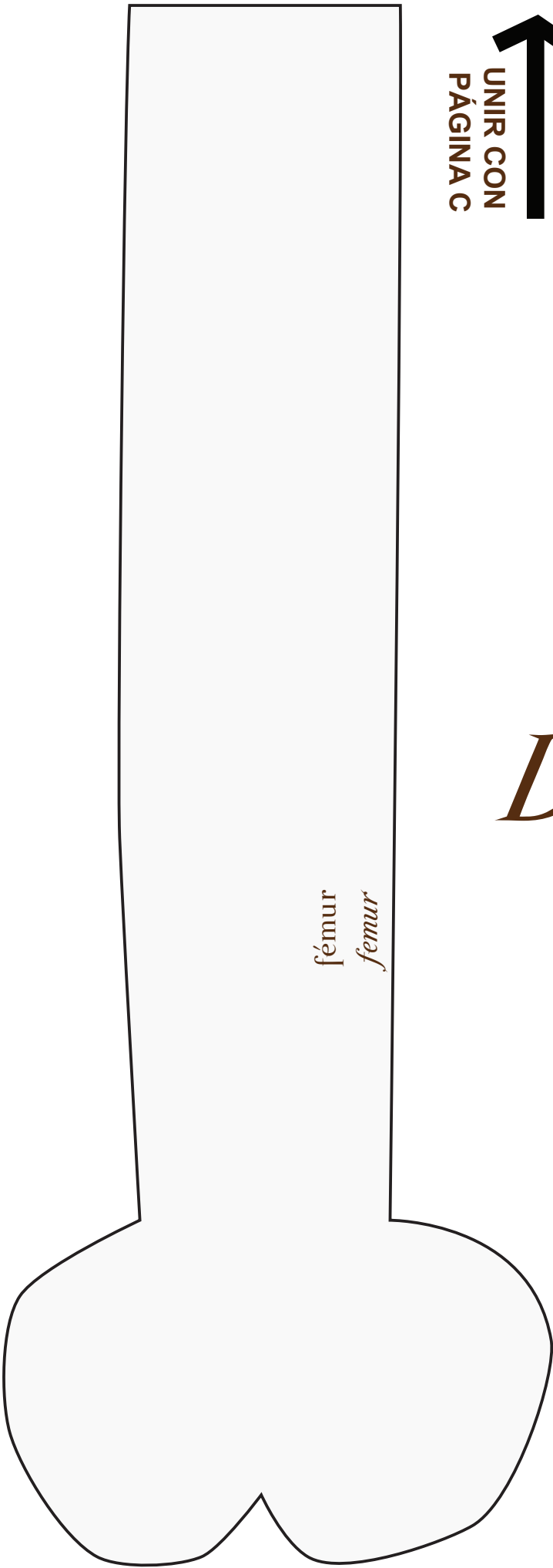


C



UNIR CON
PÁGINA D






fémur
femur

UNIR CON
PÁGINA C

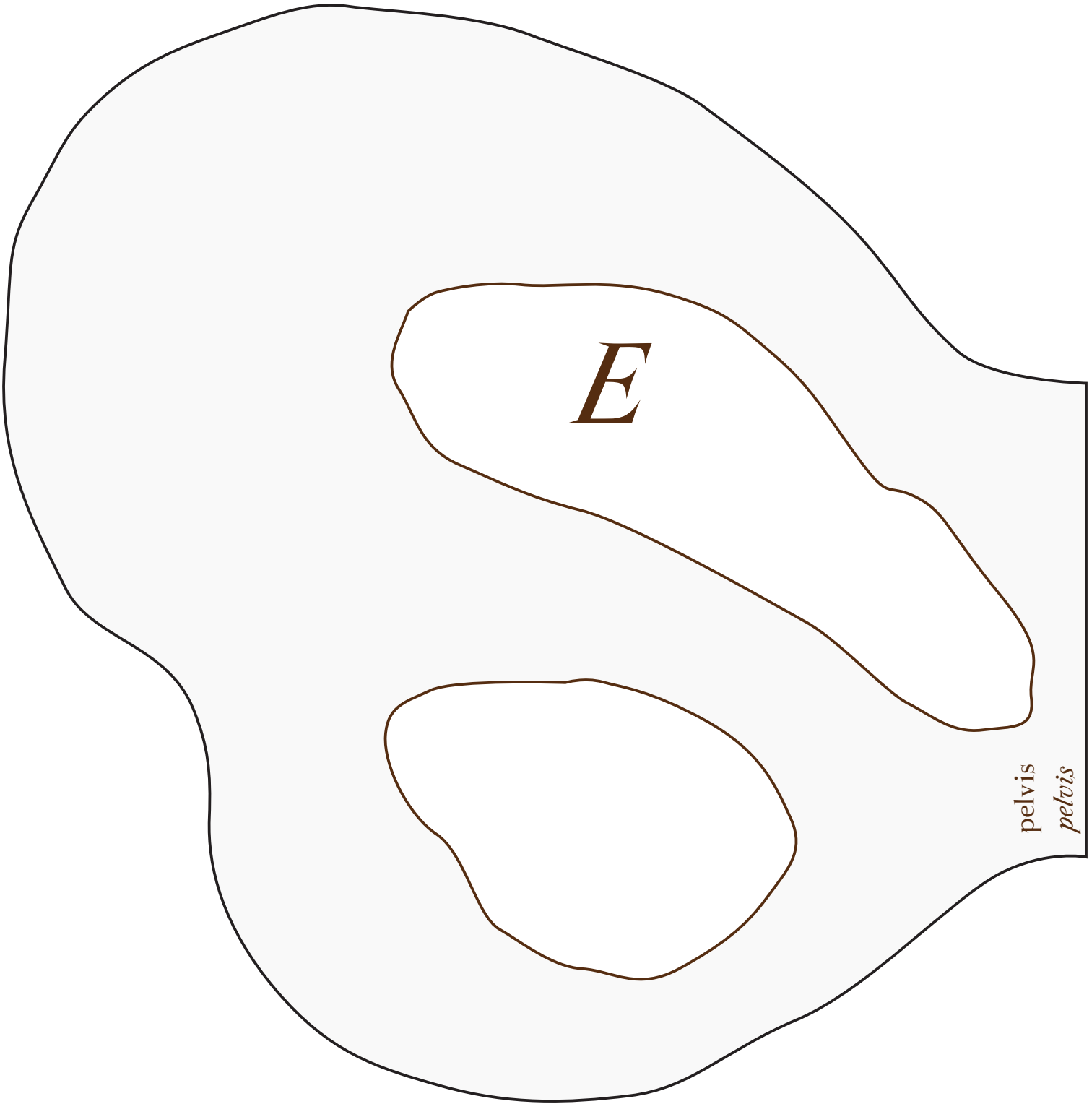


D



hueso parte inferior pierna
lower leg bone





pelvis
pelvis

